PATIENT CARE THEORY 2

UNIT 7, PART 1: Pediatric Airway

Marilyn Niffin BSc, ACP
Professor Georgian College
Winter 2020, 2021, 2023

Introduction

- Children are not just little adults
- There are many physiological differences
  - Larger occiput/ head (this changes as they grow
    - Positioning very important – padding under shoulders graduating to padding under the head
  - Tongue – proportionally larger in the oropharynx compared to adults
  - Larynx –higher up than in adults (opposite C2, C3)
  - Epiglottis – flat and flexible in the adult and c-shaped, shorter and stiffer in the pediatric

- Vocal cords – more anterior and lower attachment creates an upward slant – jaw thrust very important to open arytenoids
- Trachea shorter, narrower and cone shaped (cricoid pressure can easily obstruct
- Chest wall – more pliable/less resistant to injury
- Residual lung capacity much smaller than an adult – become hypoxic more quickly

Airway

- Anatomy increases upper airway obstruction risk
- resistance to air flow is inversely proportional to the fourth power of the radius of the airway
- One mm of concentric edema in a newborn trachea (radius approximately 2 mm) increases resistance about 16 times
- head is relatively larger: naturally flexed in supine position – this in itself can lead to obstruction
  - Large head
  - Short neck
  - Small mandible
  - Large, posteriorly placed tongue

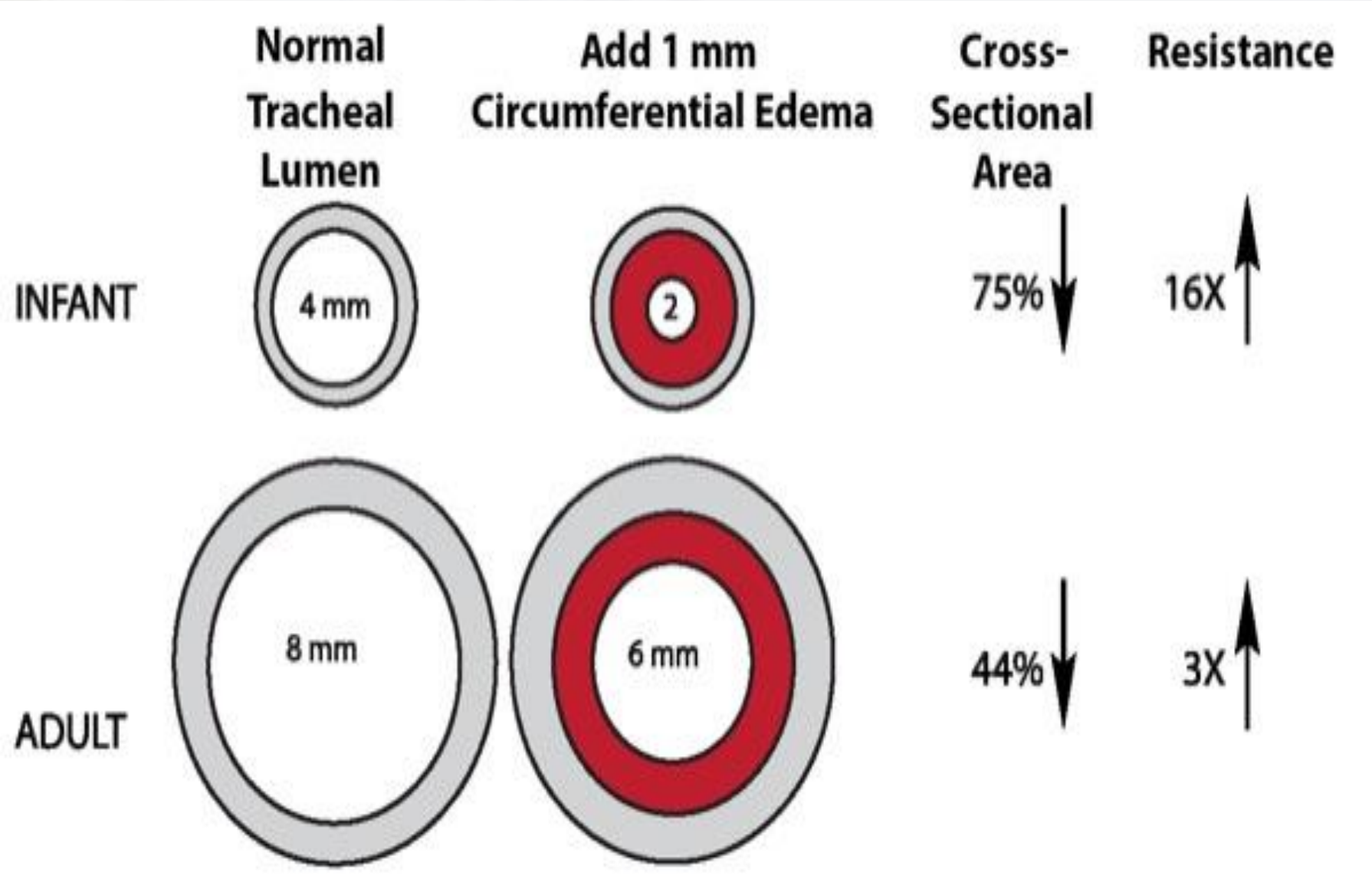
Normal Tracheal Lumen
Add 1 mm Circumferential Edema
Cross-Sectional Area
Resistance
INFANT
4 mm
2
75%
16X
ADULT
8 mm
6 mm
44%
3X

Airway

narrowest point below glottis, whereas in adults its at glottis. makes taking obstructions out difficult (as you can't bypasss vocal chords)

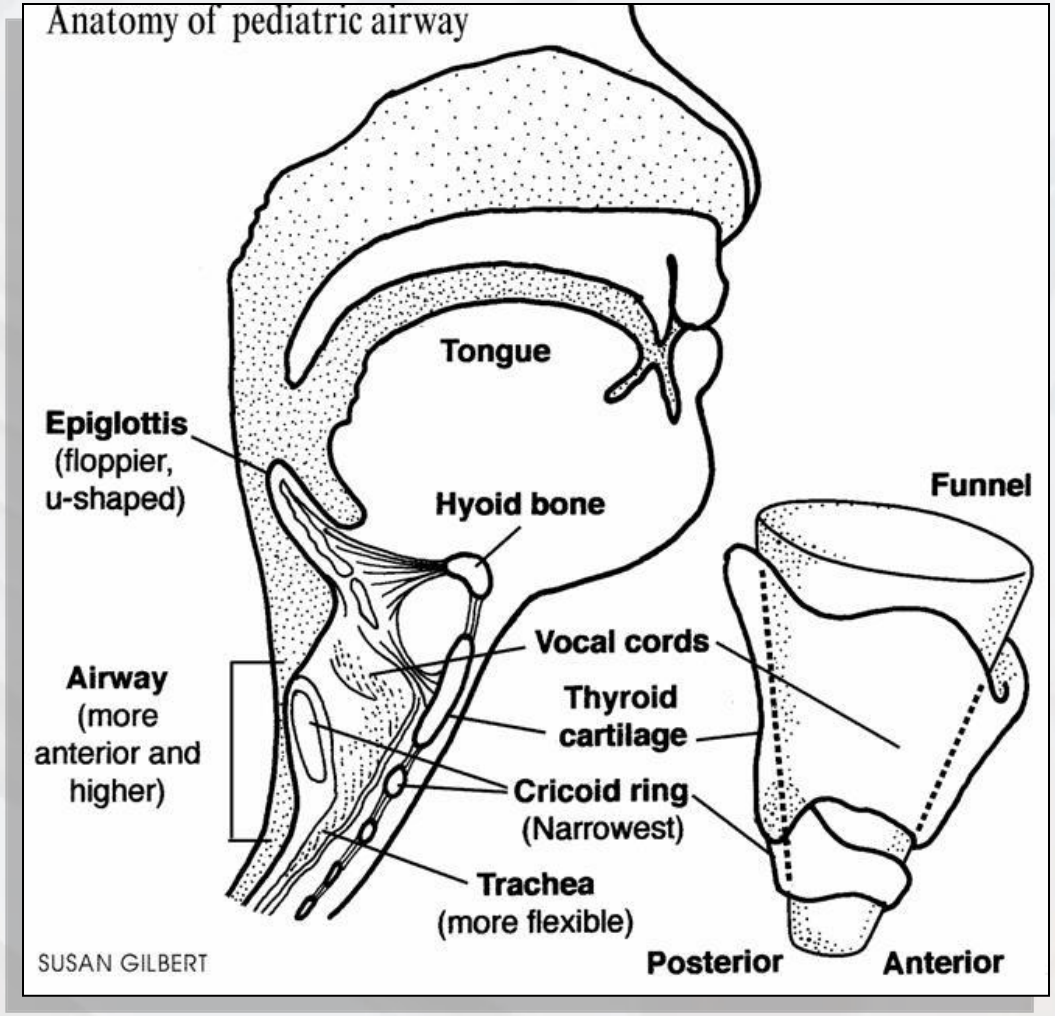

Adult Vs Peds

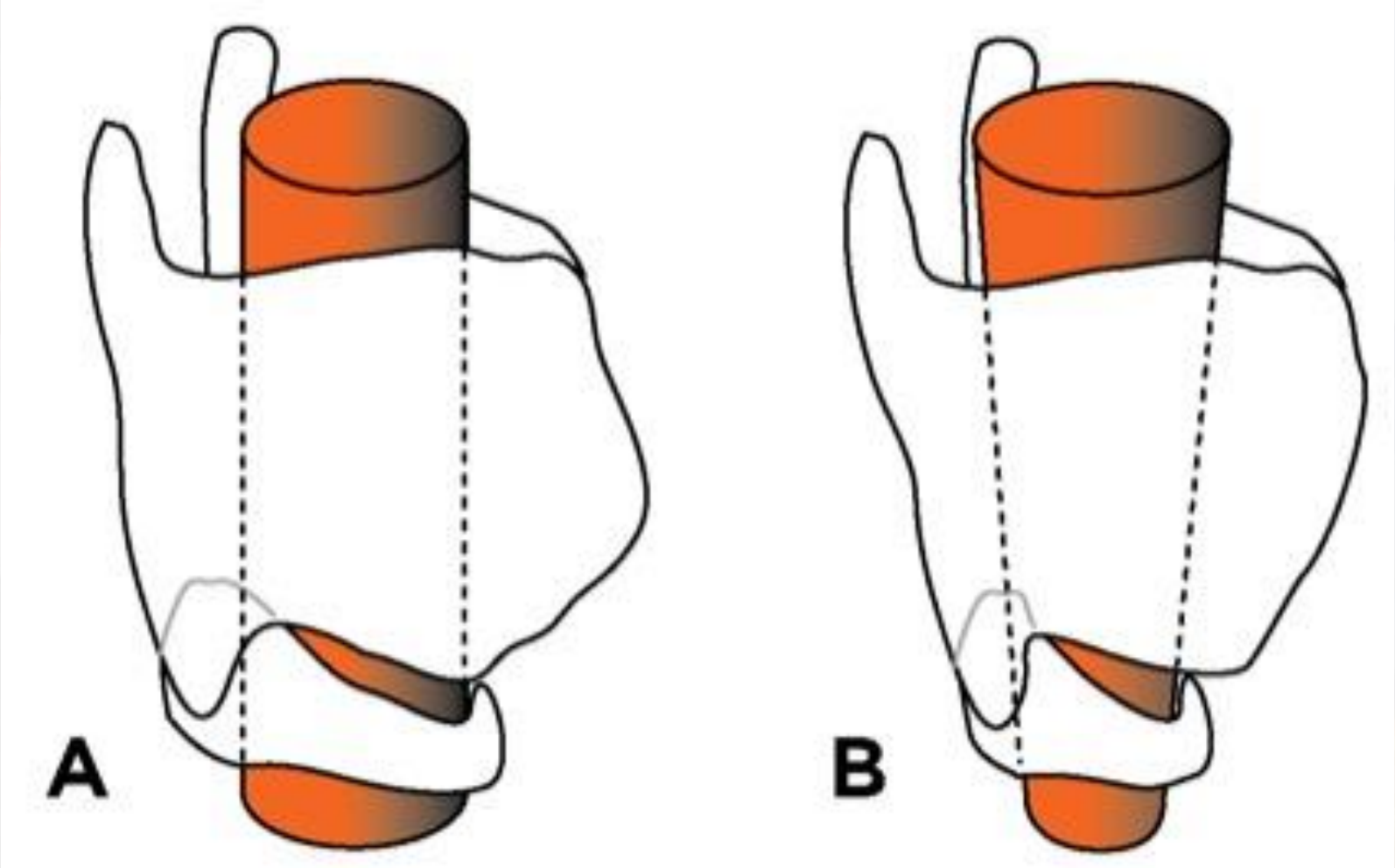

Airway

obligate nose breathers

- Neck over-extension may obstruct airway due to high glottis and pliable trachea (newborn, infant, toddler, small child)
- Use sniffing position if neck injury *not* suspected
- Chin lift particularly important to get tongue out of airway

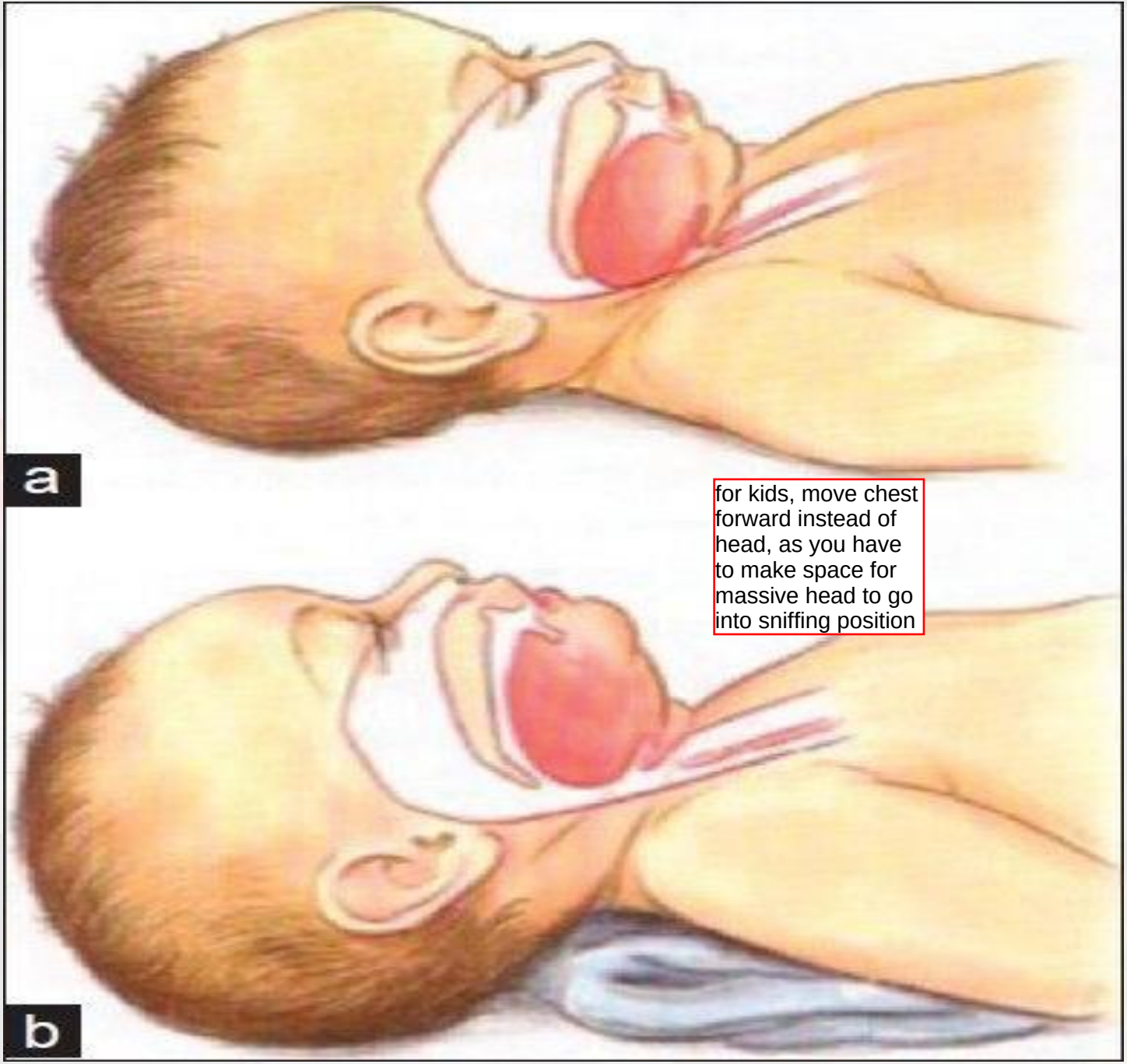

for kids, move chest forward instead of head, as you have to make space for massive head to go into sniffing position

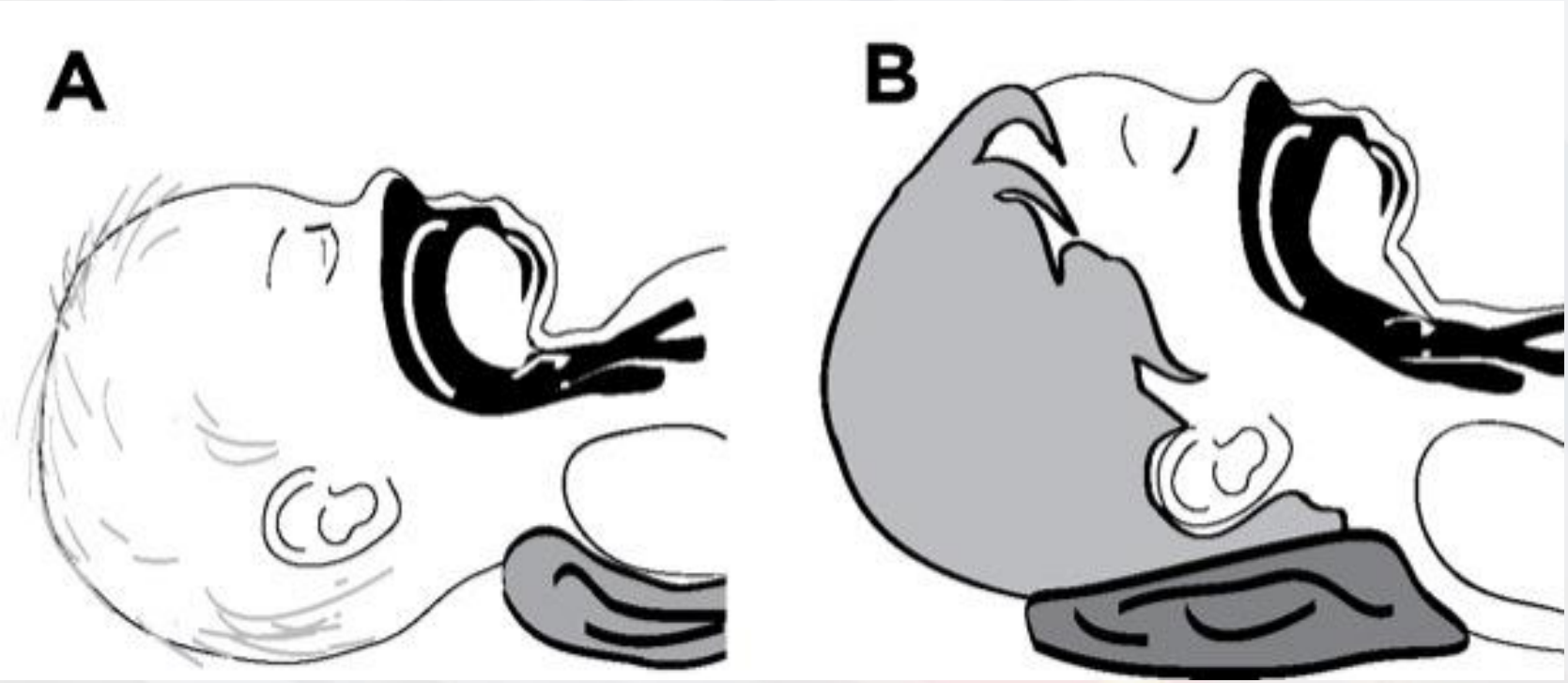

- https://www.anesthesiologynews.com/aimages/2019/ANSE0819_0051_j_600.jpg

Airway Obstruction

- young children (especially 12-24 months of age) have a relative propensity to aspirate foreign bodies (food, coins)
- start with basic maneuvers!
  - follow current HSFO guidelines
  - Back blows/chest thrusts/abdominal thrusts

5 back, 5 chest in rotations.
keep head below body to utilize gravity

use bulb suction in younger infants

suctions powers
neonates - 50-60
infants - 80-100
kids - 200-250
adults - 350-500
GO LOW

Airway Obstruction - Arrest

- In the event of an arrest secondary to a foreign body obstruction (FBAO) treat according to the medical cardiac arrest medical directive
  - Consider early transport (following 1 analysis)
    - Unless in VF or VT – provide at least 3 defibrillations before moving the patient
  - Contraindicated for TOR

Croup

can only treat <=7yo patients, must patch if older

- Laryngotracheobronchitis (croup)
- *Subglottic structure area affected*
- Upper airway swelling as a result of viral infection causing varying degrees of airway obstruction
- Most common in children age 3 mo. to 3 years old
- Uncommon in children over 6

Croup

History:

- URTI with low fever, runny nose, mild cough
- evening → night develops stridor and barking cough
- Anxious, upset - more comfortable sitting up

Croup

Physical Exam findings:

- Barking, seal-like cough that progresses to loud stridor
- If stridor present, usually heard without auscultation
- Low grade fever
- Slow onset 24 to 72 hours after symptoms of URTI present
- Usually no drooling present*
- Accessory muscle use (retractions)

Croup

Impending respiratory failure:

- **≤ 3 word dyspnea**
- **Altered mental status** (fatigue, restlessness)
- Increased retractions
- Decreased breath sounds with decreasing stridor means less air
- Pallor and Cyanosis

Croup

Management

- interfere as little as possible with the child
  - How can you properly assess without approaching child?
- keep the child with the parent
- oxygen by mask or “blow by” if the mask is not tolerated – humidified if available
- exposure to cool air (as season permits)
- nebulized Epinephrine
- Dexamethasone
- PPV prn
- transport

Croup

Indications

Current history of URTI;

AND

Barking cough or recent history of a barking cough.

Conditions

	EPINEPHrine
Age	≥ 6 months to < 8 years
LOA	N/A
HR	<200 bpm
RR	N/A
SBP	N/A
Other	Stridor at rest

	dexamethasone
Age	≥ 6 months to < 8 years
LOA	Unaltered
HR	N/A
RR	N/A
SBP	N/A
Other	For mild, moderate and severe croup

Croup

- Steroids received within the last 48 hours refer to those that are “systemic” and not a Rx inhaler

Contraindications

EPINEPHrine
Allergy or sensitivity to EPINEPHrine

Dexamethasone
Allergy or sensitivity to steroids
Steroids received within the last 48 hours
Unable to tolerate oral medications

Croup

Treatment

Consider EPINEPHrine		
	Weight	**Weight**
	<10 kg	≥10 kg
	Route	**Route**
	NEB	NEB
	Concentration	**Concentration**
	1 mg/mL = 1:1,000	1 mg/mL = 1:1,000
Dose	2.5 mg	5 mg
Max. single dose	2.5 mg	5 mg
Dosing interval	N/A	N/A
Max. # of doses	1	1

Consider Dexamethasone	
	Age
	≥ 6 months to <8 years
	Route
	PO
Dose	0.5 mg/kg
Max. single dose	8 mg
Dosing interval	N/A
Max. # of doses	1

Note: All cases of severe respiratory distress and the presence of stridor at rest should be treated with epinephrine first.
For milder cases that do not require epinephrine, dexamethasone may be administered alone.

Epiglottitis

- Supraglottic structures
- Older children 2 yrs to 7 yrs (seen in adults as well)
- Rapid onset
- Sudden onset of high fever
- SOB, stridor, retractions, cyanosis
- Drooling usually present
- Sit in sniffing position
- May progress to complete A/W obstruction & resp arrest

Infant

Toddler

Adult

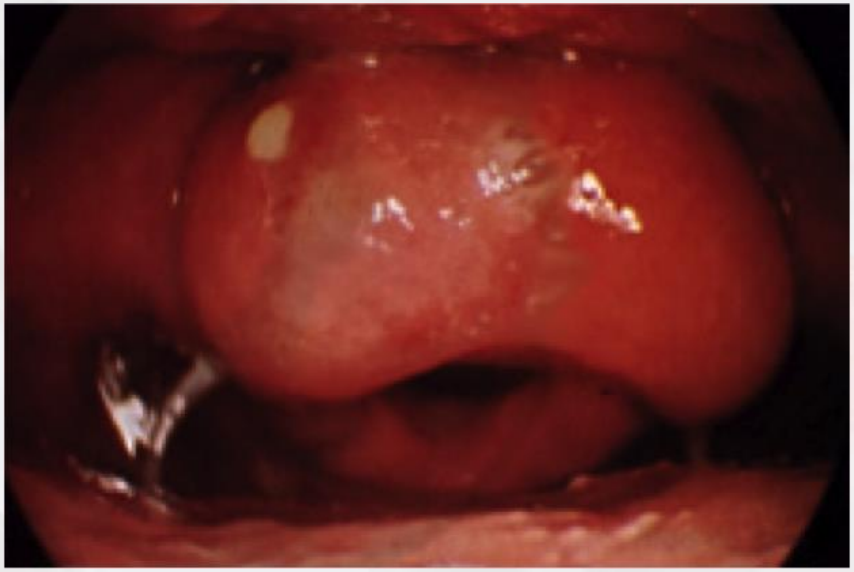

Epiglittitis

Management

- Avoid distressing the child
- Allow child to stay with parent
- Do not inspect the airway
- Do not apply oxygen – give mask to parent to hold nearby if possible
  - Respiratory/cardiac arrest
  - PPV with a BVM (may or may not have a/e due to swelling of structure)

Croup vs. Epiglottitis

Croup:

- Subglottic area
- Younger child 3mos to 7 years
- Gradual onset, hx recent URTI (over several hours)
- barking cough, +/-stridor
- No or low fever
- No drooling (typically)

Epiglottitis:

- Supraglottic structures
- Older children 2 yrs to 7 yrs
- More Rapid onset
- Sudden onset of high fever
- SOB, stridor, retractions, cyanosis
- Drooling usually present
- Sit in sniffing position
- May progress to complete A/W obstruction & resp arrest

MANAGEMENT

Pediatric Triangle – Form General Impression

Muscle tone
Interactiveness
Consolable?
Look/Gaze
Speech/Cry

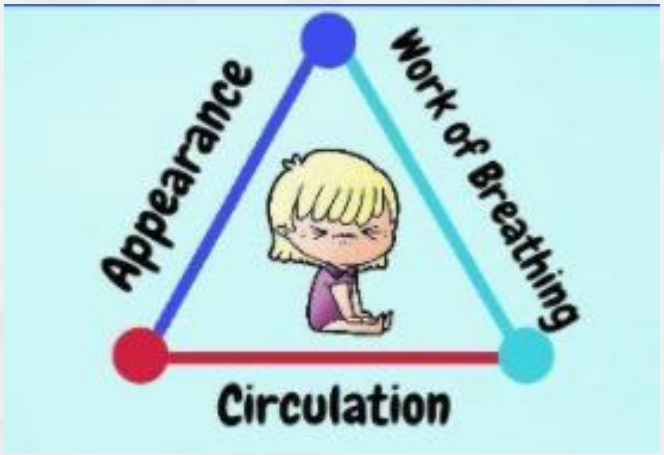

Abnormal breath sounds
Position
Head bobbing
Retractions
Gasping
Grunting
Nasal flaring

Pallor
Mottling
Cyanosis
Temperature

palpable pulses
blood pressure
bleeding
Turgor/mucous membranes

unrealiable bcs kids can compensate BP well

HR x SV = CO

They increase HR and vasoconstrct

Neonates can't vasoconstrict, and have less contractile heart muscles (starlings law doesn't apply)

Management Summary

- Supportive care
  - Ensure a patent airway
  - Slight hint of an A/W problem is life-threatening until proven otherwise
  - Suction PRN **
  - Keep child with parent (with some exceptions)
  - O_2 at high concentration for dyspnea
  - Nebulized epi for A/W obstruction due to croup
  - PPV with $ETCO_2$ prn
    - Hypoxia is a more common cause of morbidity and mortality than in adults

Airway Patency - OPA

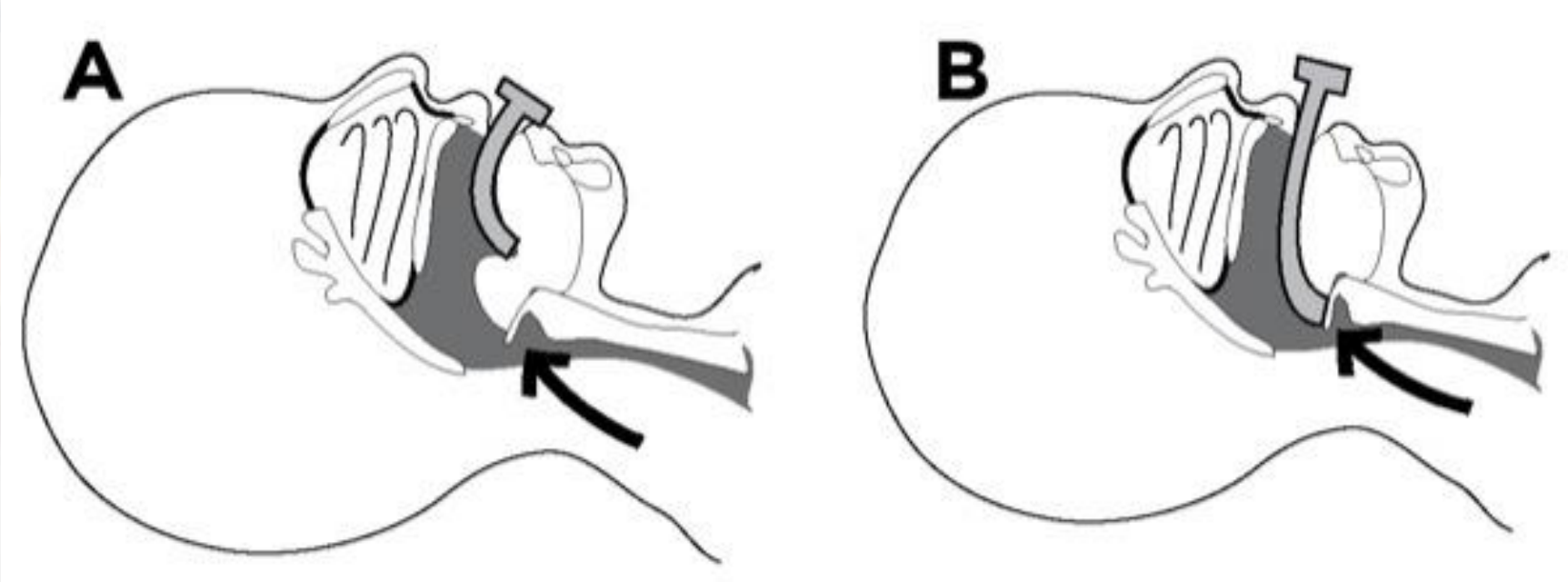

- too small places the tip in the middle of the tongue, bunching the tissue and worsening obstruction
- Too large extends from the mouth and prevents sealing the mask over the face. Also, it can fold the epiglottis down over the glottic opening and worsen obstruction

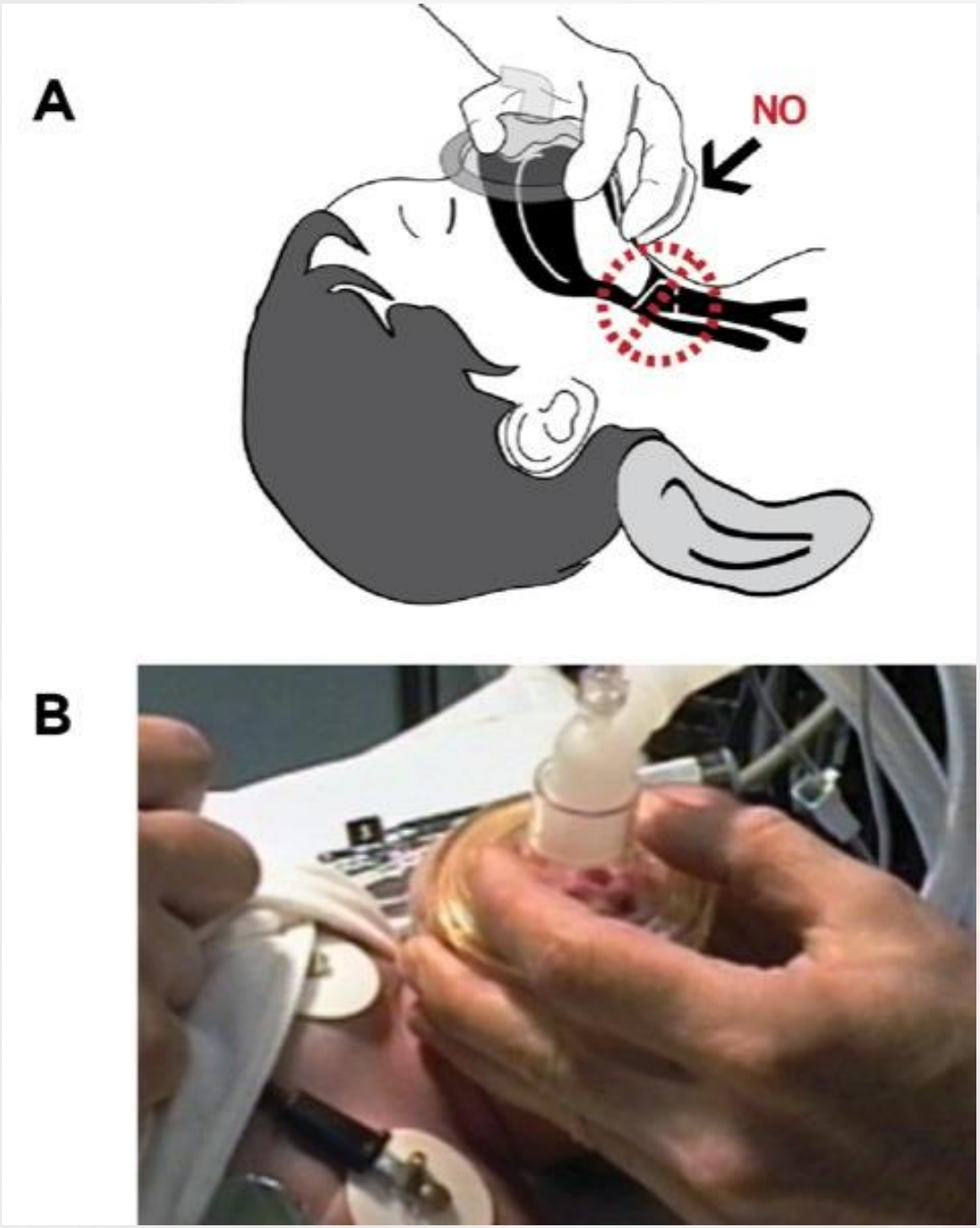

Ensure that you do not apply pressure over the soft tissue of the child's throat – this can increase airway obstruction by pushing the tongue and epiglottis back over the laryngeal outlet, and by compressing the soft laryngeal cartilages

Ventilation & Oxygenation

- How do you know PPV is needed?
  -
  -
  -
  -
  -
  -
  -
  -
  -

Ventilation & Oxygenation

- How do you know when ventilation / oxygenation are effective?
  -
  -
  -
  -
  -
  -
  -

Ventilation & Oxygenation

- How do you know when ventilation / oxygenation are effective?
  - Chest rises (symmetrically)
  - No A/E in the stomach
  - Colour improves
  - LOA improves
  - HR comes down / or back up to normal
  - SpO_2 improves
  - ECG rhythm – ectopy diminishes/disappears

Ventilation - Barotrauma

- It is very important to know the Tv of your patient
- Walls of a child's lungs are thinner and less mature
- They are more fragile and more easily damaged

- Using the appropriately sized BVM and carefully monitoring compliance can greatly reduce the risk of over-inflation and barotrauma

QUESTIONS